

Original Article

# Ultrasonographic scoring system score versus liver stiffness measurement in prediction of cirrhosis

Kyoung Min Moon<sup>1\*</sup>, Gaeun Kim<sup>2\*</sup>, Soon Koo Baik<sup>3,4,5</sup>, Eunhee Choi<sup>5</sup>, Moon Young Kim<sup>3,4,5</sup>, Hyoun A Kim<sup>3</sup>, Mee Yon Cho<sup>6</sup>, Seung Yong Shin<sup>3</sup>, Jung Min Kim<sup>3</sup>, Hong Jun Park<sup>3</sup>, Sang Ok Kwon<sup>3</sup>, and Young Woo Eom<sup>4</sup>

<sup>1</sup>Department of Internal Medicine, Konyang University College of Medicine, Daejeon; <sup>2</sup>Department of Nursing, Keimyung University College of Nursing, Daegu; <sup>3</sup>Department of Internal Medicine, Yonsei University Wonju College of Medicine, Wonju; <sup>4</sup>Cell Therapy and Tissue Engineering Center, Yonsei University Wonju College of Medicine, Wonju; <sup>5</sup>Institute of Lifestyle Medicine, Yonsei University Wonju College of Medicine, Wonju; <sup>6</sup>Department of Pathology, Yonsei University Wonju College of Medicine, Wonju, Korea

**Background/Aims:** We compared the cirrhosis-prediction accuracy of an ultrasonographic scoring system (USSS) combining six representative sonographic indices with that of liver stiffness measurement (LSM) by transient elastography, and prospectively investigated the correlation between the USSS score and LSM in predicting cirrhosis.

**Methods:** Two hundred and thirty patients with chronic liver diseases (187 men, 43 women; age, 50.4±9.5 y, mean±SD) were enrolled in this prospective study. The USSS produces a combined score for nodularity of the liver surface and edge, parenchyma echogenicity, presence of right-lobe atrophy, spleen size, splenic vein diameter, and abnormality of the hepatic vein waveform. The correlations of the USSS score and LSM with that of a pathological liver biopsy (METAVIR scoring system: F0–F4) were evaluated.

**Results:** The mean USSS score and LSM were 7.2 and 38.0 kPa, respectively, in patients with histologically overt cirrhosis (F4,  $P=0.017$ ) and 4.3 and 22.1 kPa in patients with fibrotic change without overt cirrhosis (F0–F3) ( $P=0.025$ ). The areas under the receiver operating characteristic (ROC) curves of the USSS score and LSM for F4 patients were 0.849 and 0.729, respectively. On the basis of ROC curves, criteria of USSS  $\geq 6$ : LSM  $\geq 17.4$  had a sensitivity, specificity, positive predictive value, negative predictive value, and accuracy of 89.2%:77.6%, 69.4%:61.4%, 86.5%:83.7%, 74.6%:51.9% and 0.83:0.73, respectively, in predicting F4.

**Conclusions:** The results indicate that this USSS has comparable efficacy to LSM in the diagnosis of cirrhosis. (*Clin Mol Hepatol* 2013;19:389-398)

**Keywords:** Ultrasonography; Elastography; Cirrhosis; Biopsy

## INTRODUCTION

Cirrhosis is a liver disease in which the hepatic architecture is destroyed, with fibrous septa surrounding regenerated or regenerating parenchymal nodules. Pathological examination of percuta-

neous biopsy remains the gold standard for assessing the extent of fibrosis and the progression of cirrhosis.<sup>1,2</sup> Although percutaneous liver biopsy (LB) is relatively safe, it is characterized by significant morbidity (3%) and mortality (0.03%).<sup>3</sup> In addition, examination of LB may result in false negative findings due to inadequate

### Abbreviations:

CLD, chronic liver disease; HCV, chronic hepatitis C virus; IRB, institutional Review Board; LB, liver biopsy; LSM, liver stiffness measurement; ROC, receiver operating characteristic; TE, transient elastography; US, ultrasonography; USSS, ultrasonographic scoring system

\*These authors made an equal contribution to this work.

### Corresponding author : Soon Koo Baik

Division of Gastroenterology and Hepatology, Department of Internal Medicine, Yonsei University, Wonju College of Medicine, 162 Ilsan-ro, Wonju 220-701, Korea  
Tel. +82-33-741-1223, Fax. +82-33-741-1228  
E-mail: baiksk@yonsei.ac.kr

Received : Oct. 21, 2013 / Revised : Nov. 6, 2013 / Accepted : Nov. 12, 2013

liver samples.

Liver stiffness measurement (LSM) by transient elastography (TE) generates an elastic wave using a vibration delivered to the right lobe of the liver through intercostal spaces and measures the propagation velocity of the elastic shear wave in the tissue, which is directly related to liver stiffness.<sup>4</sup> This method was first developed to evaluate chronic hepatitis C virus (HCV) patients in France. Recently, LSM has been successfully used for the assessment of fibrosis in other chronic liver diseases.<sup>4-12</sup> Currently, although controversies still remain, LSM by TE seems to be a promising non-invasive method to estimate liver fibrosis.<sup>5,6,13</sup>

Ultrasonography (US) has been widely used for several decades in the diagnosis of cirrhosis.<sup>14-23</sup> Many attempts to assess hepatic fibrosis using US features have been made, with the aim of replacing the invasive diagnosis of cirrhosis. In a study by Lu et al, US examination indicated that the thickness of the liver capsule, maximum oblique diameter of the right liver, diameter of the splenic vein, and thickness of the spleen were correlated with the staging of liver fibrosis. While the use of isolated US factors lacks accuracy and reliability, the combination of multiple US features was quite sensitive and specific in the diagnosis of hepatic fibrosis.<sup>24</sup> Therefore, we developed an ultrasonographic scoring system (USSS) composed of 6 US features: liver surface and edge nodularity, parenchyma echogenicity, presence of right lobe atrophy, spleen size, splenic vein diameter, and abnormality of hepatic waveform.

In terms of their accuracy and reproducibility, both LSM and US have high potential as non-invasive techniques for the evaluation of fibrosis in chronic liver disease (CLD) patients.<sup>4</sup> However, no comparison study between US and LSM has been performed to evaluate their usefulness in predicting cirrhosis.

## SUBJECTS AND METHODS

### Subjects

From October 2007 to February 2011, a total of 230 patients admitted to the Wonju College of Medicine University Hospital with CLD who underwent LB were included in this study. The following features were prospectively measured and analyzed: age, sex, height, weight, etiology of cirrhosis, Child class, albumin, total bilirubin, prothrombin time, platelet count, LSM by TE, and 6 US features (liver surface and edge nodularity, parenchyma echogenicity, right lobe atrophy, spleen size, splenic vein diameter, and hepatic vein waveform). All patients were studied using the 2 non-invasive methods: TE (Fibroscan; Echosens, Paris, France) with a 3.5-MHz M probe and US (Prosound  $\alpha$ 10; Aloka, Tokyo, Japan) with a 3.5-MHz convex probe.

The Institutional Review Board (IRB) of the hospital approved the protocol, and written informed consent to participate in the study was received from all participating patients. The study was conducted according to the principles of the Declaration of Helsinki (revised in Edinburgh 2000).

### Methods

#### Ultrasonographic scoring system

The USSS is composed of 6 US features (Table 1) that have been reported to demonstrate associations with the presence of cirrhosis and are currently utilized in clinical practice: liver surface and edge nodularity, parenchyma echogenicity, presence of right lobe atrophy, spleen size, splenic vein diameter, and abnormality of hepatic vein waveform. A single operator (S.K.B) performed the ul-

**Table 1.** Ultrasonographic and Doppler features used to evaluate liver cirrhosis

Clinical features	Score		
	0	1	2
Surface and edge	smooth and sharp	mildly irregular and mildly blunted	irregular and blunted
Parenchyma echogenicity	Fine	mildly coarse	coarse
Right lobe atrophy	absent <sup>*</sup>		present <sup>†</sup>
Spleen size (cm)	<10	10-14	>14
Splenic vein diameter (cm)	<0.7	0.7-0.9	>0.9
Hepatic vein waveform	Triphasic	bi or monophasic	

The total score from six ultrasonographic indices including surface nodularity and edge shape (0-2), parenchyma echogenicity (0-2), right lobe atrophy (0-2), spleen size (0-2), splenic vein diameter (0-2) and hepatic vein waveform (0-1) was calculated.

<sup>\*</sup>Right lobe maximal oblique diameter >7 cm with no subphrenic ascites.

<sup>†</sup>Right lobe maximal oblique diameter <10 cm with subphrenic ascites.

**Table 2.** Results of uni- and multivariate analyses for the ultrasonographic features related to cirrhosis

	<b>P-value</b>		
<b>Univariate Analysis</b>			
Caudate lobe enlargement	0.52		
Surface nodularity and blunting edge	<0.05		
Parenchyma echogenicity	<0.05		
Rt. lobe atrophy	<0.001		
Portal vein dilatation	<0.05		
Portal vein velocity	<0.05		
Portal vein flow	<0.05		
Spleen size	<0.05		
Splenic vein diameter	<0.05		
Splenic vein velocity	<0.05		
Splenic vein flow	0.07		
Hepatic vein wave form	<0.001		
GB wall thickness	1.03		
	<b>Odds ratio</b>	<b>95% CI</b>	
		<b>Lower</b>	<b>Upper</b>
<b>Multivariate Analysis</b>			
Surface and edge (grade 0 vs. 1)	1.23	1.013	1.473
Surface and edge (grade 0 vs. 2)	2.09	1.117	2.365
Parenchyma (grade 0 vs. 1)	1.06	1.010	1.342
Parenchyma (grade 0 vs. 2)	2.24	1.423	2.515
Rt. lobe atrophy (absent vs. present)	2.23	1.117	2.347
Spleen size (grade 0 vs. 1)	1.19	1.036	1.634
Spleen size (grade 0 vs. 2)	1.92	1.027	2.014
Splenic vein diameter (cm) (grade 0 vs. 1)	1.35	1.165	2.016
Splenic vein diameter (cm) (grade 0 vs. 2)	2.17	1.178	2.767
Hepatic vein wave form ( grade 0 vs. 1)	1.36	1.102	1.761

A multivariate analysis for ultrasonographic features associated with cirrhosis was conducted using binary logistic regression analysis. The factors with  $P < 0.1$  in univariate analyses were included in multivariate analysis using enter method.

trasound examination to determine the USSS.

Because combined USSS has not been utilized widely in previous studies, no gold standard has been established for the selection of features to include in the USSS. Therefore, we measured 13 US features and analyzed the relationship between each feature and the degree of hepatic fibrosis. As shown in Table 2, 10 features demonstrated statistical significance levels of  $P < 0.05$  in univariate analysis and 3 features (caudate lobe enlargement, splenic vein flow and gallbladder thickness) were nonsignificant statistically. A multivariate analysis for ultrasonographic features

associated with cirrhosis was then conducted using binary logistic regression analysis. The factors with  $P < 0.1$  in univariate analysis were included in multivariate analysis. In multivariate analysis, 6 representative sonographic features ultimately demonstrated statistical significance. We used the odds ratio resulting from multivariate analysis to weight the features in the scoring system.

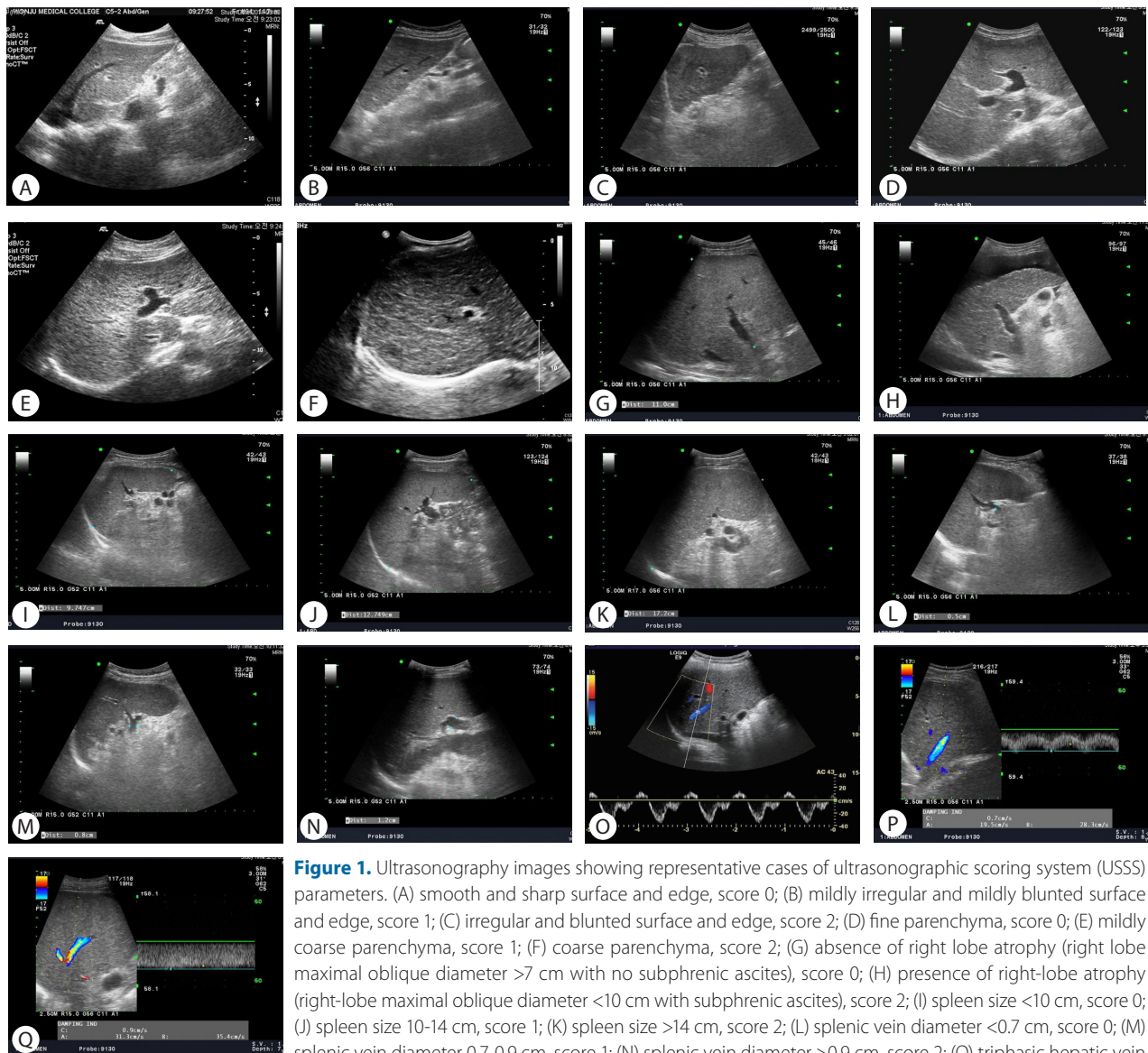
The measurement and evaluation of the features was performed in accordance with methods described in the literature,<sup>14,15,17,19-24</sup> which were scored according to the following criteria. Surface and edge were distinguished as smooth surface and sharp edge (=0),

mild uneven or waveform surface and mildly blunted edge (=1), and undulated or irregular nodular surface and blunted edge (=2). Parenchyma was classified as homogeneous appearance (=0), heterogeneous appearance with fine scattered hypoechoic and hyperechoic areas (=1), and coarse irregular pattern (=2). Right lobe atrophy was considered absent (=0) when maximal oblique diameter was larger than 7 cm with no subphrenic ascites and present (=2) when less than 10 cm with subphrenic ascites. Spleen size was calculated from the craniocaudal maximal length and considered normal (=0) when less than 10 cm, mild splenomegaly (=1) between 10 and 14 cm, and splenomegaly (=2) when larger

than 14 cm. Splenic vein diameter was measured as the largest antero-posterior diameter and considered normal (=0) when less than 0.7 cm, mildly dilated (=1) when between 0.7 cm and 0.9 cm, and frankly dilated (=2) when larger than 0.9 cm. Hepatic vein waveform was considered normal (=0) when triphasic and abnormal (=1) when bi- or monophasic. Ultrasonographic images of representative patients are shown in Figure 1.

### Liver stiffness measurement

TE measures the liver stiffness in a volume that approximates a cylinder 1 cm wide and 4 cm long, and the results were expressed



in kilopascals (kPa). The technique was performed by 2 operators (K.M.M. and M.Y.K.) with 4 years experience performing LSM by TE with a 3.5-MHz M probe and trained for proficiency by the manufacturer (Echosens, Seoul, Korea), who were blinded to the USSS results. At least 10 measurements were carried out in each patient. Measurements were performed on the right lobe of the liver through the intercostal spaces between 25 and 65 mm from the skin surface, with patients lying in the dorsal decubitus position with the right arm in maximal abduction. The median value (expressed in kPa) was considered as representative of the liver elastic modules.

### Reproducibility and inter-operator variability of USSS and LSM

To assess the reproducibility of this method, one operator (M.Y.K.) evaluated day-to-day variability with repeated studies of both USSS and LSM in 10 healthy volunteers over 5 consecutive days by obtaining coefficients of variation (calculated by dividing the standard deviation by the mean and multiplying by 100). Thus, higher reproducibility is associated with a lower coefficient of variation. The inter-operator variability between the 2 operators (K.M.M. and M.Y.K.) for determining both USSS and LSM, expressed as a kappa value, was analyzed in 10 healthy volunteers.

### Histological examination

All biopsy specimens were analyzed independently by an experienced hepatopathologist (M.Y.C.) who was blinded to patients' clinical data including USSS, LSM, and clinical data. LB specimens were fixed in formalin and paraffin embedded. Four-micrometer-thick sections were stained with hematoxylin and eosin (H&E) and Masson trichrome. LB specimens unsuitable for fibrosis assessment (LB length <15 mm or less than 6 portal tracts) were excluded from analysis. LSM and USSS were performed on the same day. LB was performed within 1 day after USSS and LSM.

Histological fibrosis scores of the liver are a mixture of descriptions of fibrotic and architectural histological changes. We classified LB specimens into 5 categories with the application of the METAVIR scoring system: lack of fibrosis (F0), portal fibrosis (F1), periportal fibrosis (F2), bridging fibrosis (F3), and cirrhosis (F4).<sup>25</sup> The patient population was then divided into 2 groups: fibrotic change without cirrhosis (F0-3) and histologically overt cirrhosis (F4).

### Statistical analysis

A multivariate analysis for ultrasonographic features associated

with cirrhosis was conducted using binary logistic regression analysis. The factors with  $P < 0.1$  in univariate analyses were included in multivariate analysis using enter method.

Results are expressed as mean  $\pm$  standard deviation. Comparisons between clinical features, USSS, laboratory tests, and histological outcome (absence or presence of cirrhosis) were analyzed by the independent-samples t test.  $P$ -values less than 0.05 were considered statistically significant. Receiver-operating characteristic (ROC) curves of LSM and USSS for F4 cases were generated. Pearson's correlation coefficient was used for the correlation analysis. Statistical analysis was performed using the Statistical Package for the Social Sciences (SPSS 18.0, Chicago, Illinois, USA).

## RESULTS

### Baseline characteristics

The general characteristics of study populations are summarized in Table 3. The mean age of participants (187 men and 43 women) was  $50.4 \pm 9.5$  years. Seventy-two patients (21.4%) demonstrated histologically no overt cirrhosis (F0-3), and 158 (78.6%) patients had fibrotic change with overt cirrhosis (F4). Sex, age, body mass index (BMI), etiology, albumin, and total bilirubin did not significantly differ between the 2 groups (all  $P > 0.05$ ), but statistically significant differences were observed in USSS, LSM, prothrombin time, and platelet count ( $P < 0.05$ ).

Fourteen patients (6.1%) were classified as F0 fibrosis stage (without fibrosis), 12 (5.2%) as F1, 20 (8.7%) as F2, 26 (11.3%) as F3, and 158 (68.7%) as F4. One hundred eighty-four patients (80.0%) demonstrated fibrosis stage  $\geq$  F3 (advanced fibrosis). The median USSS and LSM (kPa) were 3.0 and 6.8 for patients with F0 fibrosis, 3.5 and 16.6 for F1, 5.0 and 9.9 for F2, 6.0 and 25.1 for F3, and 7.0 and 42.2 for F4, respectively (Fig. 2-A and -B). In addition, both USSS and LSM demonstrated significant positive correlations with the histological grade of fibrosis ( $P < 0.001$ ). Pearson's correlation coefficient for USSS and LSM was  $r = 0.432$  ( $P < 0.001$ ).

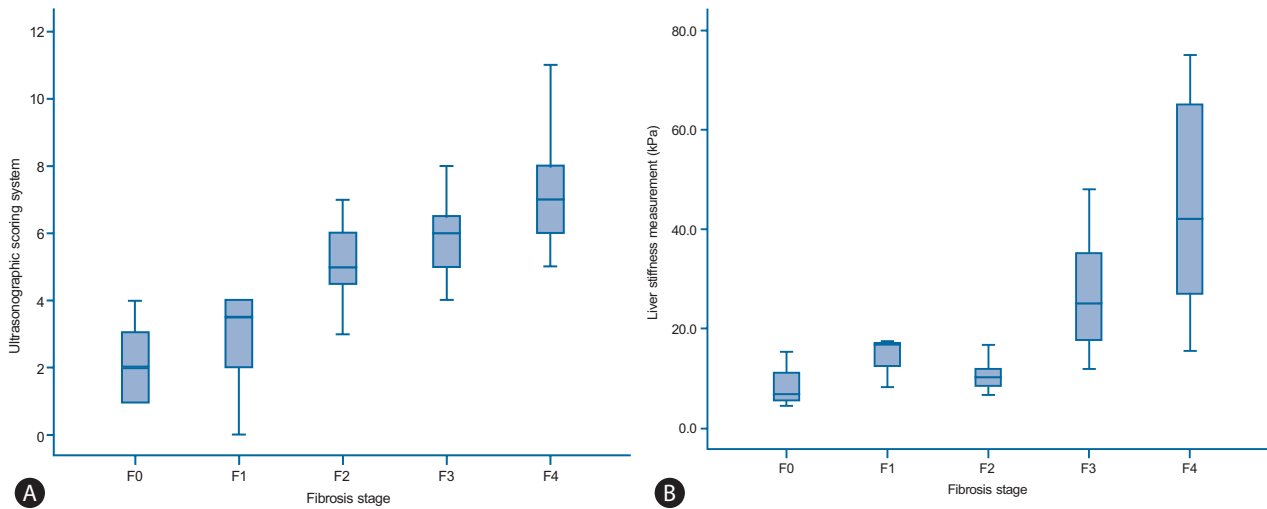
### Reproducibility and inter-operator variability of USSS and LSM

In 10 healthy control subjects, the coefficients of variation of USSS and LSM were 7% and 8%, respectively. The kappa values of USSS and LSM were calculated as 0.85 and 0.83, respectively, indicating excellent reproducibility and concordance between the

**Table 3.** General characteristics of the 230 study patients

Clinical features	Overall population		Histological stage		P-value (F0-3&F4)
	(n=230)	F3-4 (n=184)	F0-3 (n=72)	F4 (n=158)	
Gender, M/ F	187/43 (81.3%/18.7%)	150/34 (81.5%/18.5%)	58/14 (80.6%/19.4%)	129/29 (81.6%/18.4%)	0.698
Age, yr	50.4±9.5	50.3±9.1	49.1±10.8	51.1±8.8	0.074
BMI, kg/m <sup>2</sup>	23.4±2.6	23.3±2.7	23.3±2.3	23.4±2.7	0.874
Etiology					0.084
Alcoholic	173 (76.2%)	136 (74.7%)	62 (87.3%)	111 (71.2%)	
HBV	32 (14.1%)	28 (15.4%)	4 (5.6%)	28 (17.9%)	
Alcoholic and HBV	10 (4.4%)	9 (4.9%)	2 (2.8%)	8 (5.1%)	
HCV	1 (0.4%)	1 (0.5%)	0 (0%)	1 (0.6%)	
Alcoholic and HCV	2 (0.9%)	1 (0.5%)	1 (1.4%)	1 (0.6%)	
Cryptogenic	9 (3.9%)	7 (3.8%)	2 (2.8%)	7 (4.4%)	
Albumin, g/dL	3.5±0.5	3.4±0.5	3.6±0.6	3.4±0.5	0.643
Total bilirubin, mg/dL	1.7±2.0	1.9±2.1	1.3±1.4	1.8±2.2	0.123
Prothrombin time, INR	1.1±0.2	1.2±0.2	1.0±0.1	1.1±0.2	0.037
Platelet count, x1,000	159.7±0.1	133.4±0.1	245.1±0.1	121.3±0.1	<0.001
Child-Pugh's score				6.5±1.5	<0.001
Class A				5.4±0.5, 89 (56.7%)	
Class B				7.5±0.7, 62 (39.5%)	
Class C				10.9±0.9, 6 (3.8%)	
USSS	6.3±2.2	7.0±1.7	4.3±2.0	7.2±1.6	0.017
LSM	36.4±21.6	41.8±19.8	16.6±10.6	44.4±19.7	<0.001

Values are expressed as mean±standard deviation or number. *P*<0.05 is denoted in bold. F3-4, advanced fibrosis; F0-3, fibrotic change without overt cirrhosis; F4, overt cirrhosis; BMI, body mass index; HBV, hepatitis B virus; HCV, hepatitis C virus; USSS, ultrasonographic scoring system; LSM, liver stiffness measurement; INR, international normalized ratio.



**Figure 2.** (A) USSS score for each fibrosis stage. The top and bottom edges of the boxes indicate the first and third quartiles, respectively, while the lines through the middle of the boxes indicate median values. The median USSS scores were 2.0 (range, 1-4), 3.5 (range, 0-4), 5.0 (range, 2-7), 6.0 (range, 4-9), and 7.0 (range, 5-11) in fibrosis stages F0-F4, respectively. (B) Liver stiffness measurement (LSM) values for each fibrosis stage. The median LSM values were 6.8 (range, 4.4-15.3), 16.6 (range, 8.2-17.3), 9.9 (range, 6.6-16.6), 25.1 (range, 11.8-48.0), and 42.2 (range, 15.5-75.0) kPa in F0-F4, respectively.

**Table 4.** Diagnostic accuracy of the ultrasonographic scoring system (USSS) for the histological grade of overt cirrhosis (stage F4)

	Se (%)	Sp (%)	PPV (%)	NPV (%)	+LR	-LR	Accuracy
USSS $\geq$ 5	95.6	48.6	80.3	83.3	1.86	0.09	0.81
USSS $\geq$ 6	89.2	69.4	86.5	74.6	2.92	0.15	0.83
USSS $\geq$ 7	69.6	90.3	94.0	57.5	7.16	0.34	0.76

Se, sensitivity; Sp, specificity; PPV, positive predictive value; NPV, negative predictive value; +LR, positive likelihood ratio; -LR, negative likelihood ratio; USSS, ultrasonographic scoring system.

2 operators.

Correlation between USSS and histological grade of overt cirrhosis (F4)

The mean USSS scores $\pm$ SD of F0-3 and F4 patients were 4.3 $\pm$ 2.0 and 7.2 $\pm$ 1.6, respectively ( $P=0.017$ ). In the prediction of overt cirrhosis (F4), area under the receiver operator characteristic curve (AUROC) was 0.849 (95% confidence interval (CI) 0.782-0.916) (Fig. 3). Based on the ROC curve, different cut-off values for USSS were determined. USSS  $\geq$ 6 had sensitivity (Se), specificity (Sp), positive predictive value (PPV), negative predictive value (NPV), +likelihood ratio (LR), -LR, and accuracy of 89.2%, 69.4%, 86.5%, 74.6%, 2.92, 0.15, and 0.83, respectively, in predicting F4. Table 4 summarizes the best results for PPV, NPV, +LR, and -LR at different USSS cut-off values. Twenty-two (9.6%) of 163 patients with USSS above 6 or more had fibrotic change without overt cirrhosis (F0-3).

### Correlation between LSM and histological grade of overt cirrhosis (F4)

The mean LSM values $\pm$ SD of the F0-3 and F4 patients were 22.1 $\pm$ 19.5 kPa and 38.0 $\pm$ 22.3 kPa, respectively ( $P=0.025$ ). In the prediction of overt cirrhosis (F4), AUROC was 0.729 (95% CI 0.637-0.820) (Fig. 3). Based on the ROC curve, different cut-off values for LSM were determined. LSM  $\geq$ 17.4 had a Se, Sp, PPV, NPV, +LR, -LR, and accuracy of 77.6%, 61.4%, 83.7%, 51.9%, 2.01, 0.36, and 0.73, respectively, in predicting F4.

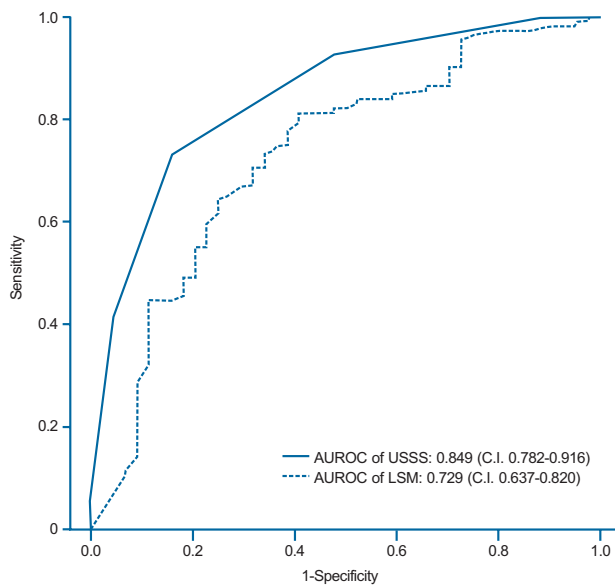
### Correlation between USSS and histological grade of advanced fibrosis (F3-4)

The mean USSS scores $\pm$ SD of F0-2 and F3-4 patients were 3.6 $\pm$ 1.9 (n=46, 11.5%) and 7.0 $\pm$ 1.7 (n=184, 88.5%), respectively ( $P=0.090$ ). In the prediction of advanced fibrosis (F3-4), AUROC

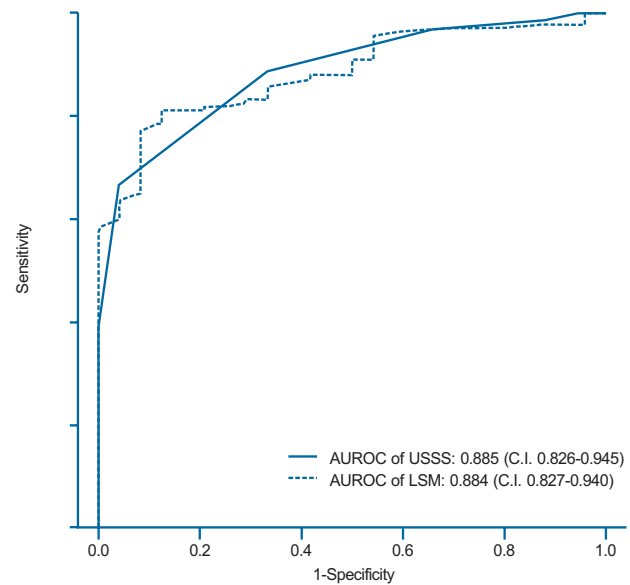
**Table 5.** Diagnostic accuracy of the USSS for advanced fibrosis (stage F3 or F4)

	Se (%)	Sp (%)	PPV (%)	NPV (%)	+LR	-LR	Accuracy
USSS $\geq$ 4	97.3	41.3	86.9	79.2	1.65	0.07	0.86
USSS $\geq$ 5	92.9	63.0	91.0	69.0	2.51	0.11	0.87
USSS $\geq$ 6	84.2	82.6	95.1	56.7	4.84	0.19	0.84

Se, sensitivity; Sp, specificity; PPV, positive predictive value; NPV, negative predictive value; +LR, positive likelihood ratio; -LR, negative likelihood ratio; USSS, ultrasonographic scoring system.



**Figure 3.** Receiver operating characteristic (ROC) curves of the USSS score and LSM for the prediction of overt fibrosis (F4). The areas under the ROC curves of the USSS score and LSM were 0.849 (standard error, 0.001; 95% confidence interval, 0.782-0.916) and 0.729 (standard error, 0.001; 95% confidence interval, 0.637-0.820), respectively.



**Figure 4.** ROC curves of the USSS score and LSM for the prediction of advanced fibrosis (F3 or F4). The areas under the ROC curves of the USSS score and LSM were 0.885 (standard error, 0.001; 95% confidence interval, 0.826-0.945) and 0.884 (standard error, 0.001; 95% confidence interval 0.827-0.940), respectively.

was 0.885 (95% CI 0.826-0.945) (Fig. 4). Based on the ROC curve, different cut-off values for USSS were determined. USSS  $\geq$ 5 had Se, Sp, PPV, NPV, +LR, -LR, and accuracy of 92.9%, 63.0%, 91.0%, 69.0%, 2.51, 0.11, and 0.87, respectively, for the prediction of F3-4. Table 5 summarizes the results for PPV, NPV, +LR, and -LR at different USSS cut-off values. Seventeen (9.0%) of 188 patients with USSS above 5 were F0-2.

### Correlation between LSM and histological grade of advanced fibrosis (F3-4)

The mean LSM $\pm$ SD for the F0-2 and F3-4 groups were 11.8 $\pm$ 5.8 kPa and 37.5 $\pm$ 22.4 kPa, respectively ( $P<0.001$ ). In the prediction of advanced fibrosis (F3-4), AUROC was 0.884 (95% CI 0.827-

0.940) (Fig. 4). Based on the ROC curve, different cut-off values for LSM were determined. LSM  $\geq$ 15.4 had Se, Sp, PPV, NPV, +LR, -LR, and accuracy of 81.82%, 79.17%, 95.58%, 44.19%, 3.93, 0.23, and 0.82, respectively, for the prediction of F3-4.

### Diagnostic performance of USSS and LSM

Table 4, 5 and Figure 3,4 show the diagnostic performance and corresponding ROC curves of USSS and LSM for predicting overt fibrosis (F4) and advanced fibrosis ( $\geq$ F3). Although LSM was a significant predictor of F4 fibrosis stage, USSS was superior to LSM (AUROC=0.849 vs. 0.729) (Table 4), and in the prediction of advanced fibrosis ( $\geq$ F3), USSS was similar to LSM (AUROC=0.885 vs. 0.884) (Table 5).



## DISCUSSION

LB has been regarded as the gold standard for estimating the severity of fibrosis and diagnosing cirrhosis.<sup>1</sup> However, noninvasive methods to estimate the stage of fibrosis have been developed,<sup>26</sup> because LB is an invasive procedure with risk of life-threatening complications.<sup>3</sup>

Recently, LSM by TE has been identified as a promising noninvasive measurement of liver elasticity, which has a significant correlation to fibrosis.<sup>8</sup> This novel method (with an average procedure time of ~5 min) is a safe alternative to LB for the evaluation of fibrosis in CLD.<sup>4</sup> Additionally, several studies reported that LSM appeared to surpass US in the prediction of cirrhosis.<sup>27</sup> However, LSM has some limitations, including the confounding effects of inflammatory activity and, to a lesser extent, steatosis on liver stiffness.<sup>28</sup> In the case of patients with narrow intercostal spaces, ascites, or elevated liver enzymes, inspection of liver elasticity is less accurate or unworkable.<sup>4,29-32</sup> In addition, LSM findings should be carefully interpreted, because food intake and the respiratory cycle affect liver stiffness values.<sup>33,34</sup>

US is an effective form of imaging that has been used by physicians for more than half a century.<sup>35</sup> Because of its low cost, ease of performance, and high patient compliance,<sup>36</sup> it has become the most common and valuable diagnostic modality for detecting not only parenchymal disease but also liver hemodynamics by Doppler imaging.<sup>37</sup> Hence, previous studies have evaluated several methods for the diagnosis of cirrhosis using various US features.

We conducted this study to clarify whether our USSS might obtain sufficiently accurate results in comparison to the histological findings for fibrosis and those obtained by LSM. Both USSS and LSM were positively correlated with histological fibrosis ( $P < 0.01$ ). USSS demonstrated a larger AUROC value compared to LSM (0.849 vs. 0.729) for the prediction of overt cirrhosis (F4) (Fig. 3). Thus, USSS may be slightly superior to LSM, although both USSS and LSM were able to assess cirrhosis and may serve as an important diagnostic tool in patients with CLD. Furthermore, a USSS cut-off value of 6 permitted the diagnosis of overt cirrhosis with sensitivity of 89.2% and specificity of 69.4% (Table 4).

This study has some limitations. First, the overall AUROC of LSM for the detection of cirrhosis (F4) was lower than that reported in previous studies, which may result from the more heterogeneous population of our study, composed of alcoholic liver disease, viral hepatitis, and cryptogenic hepatitis. Second, Liver stiffness is known to depend on the architecture of fibrosis, which is affected by its etiology. Further longitudinal studies should com-

pare USSS with LSM among a homogeneous group with the same disease etiology.

In conclusion, this study demonstrated that our USSS is able to be a diagnostic tool to evaluate the degree of hepatic histological fibrosis as an alternative to LSM.

## Acknowledgments

This study was supported by a grant of the Korea Healthcare technology R&D Project, Ministry of Health and Welfare, Republic of Korea (HI10C2020).

## Conflicts of Interest

The authors have no conflicts to disclose.

## REFERENCES

1. Bravo AA, Sheth SG, Chopra S. Liver biopsy. *N Engl J Med* 2001;344:495-500.
2. Jun DW, Cho YK, Sohn JH, Lee CH, Kim SH, Eun JR. A study of the awareness of chronic liver diseases among Korean adults. *Korean J Hepatol* 2011;17:99-105.
3. Garcia-Tsao G, Boyer JL. Outpatient liver biopsy: how safe is it? *Ann Intern Med* 1993;118:150-153.
4. Sandrin L, Fourquet B, Hasquenoph JM, Yon S, Fournier C, Mal F, et al. Transient elastography: a new noninvasive method for assessment of hepatic fibrosis. *Ultrasound Med Biol* 2003;29:1705-1713.
5. Castéra L, Vergniol J, Foucher J, Le Bail B, Chanteloup E, Haaser M, et al. Prospective comparison of transient elastography, Fibrotest, APRI, and liver biopsy for the assessment of fibrosis in chronic hepatitis C. *Gastroenterology* 2005;128:343-350.
6. Talwalkar JA, Kurtz DM, Schoenleber SJ, West CP, Montori VM. Ultrasound-based transient elastography for the detection of hepatic fibrosis: systematic review and meta-analysis. *Clin Gastroenterol Hepatol* 2007;5:1214-1220.
7. Kim KM, Choi WB, Park SH, Yu E, Lee SG, Lim YS, et al. Diagnosis of hepatic steatosis and fibrosis by transient elastography in asymptomatic healthy individuals: a prospective study of living related potential liver donors. *J Gastroenterol* 2007;42:382-388.
8. Castera L, Forns X, Alberti A. Non-invasive evaluation of liver fibrosis using transient elastography. *J Hepatol* 2008;48:835-847.
9. Zioli M, Handra-Luca A, Kettaneh A, Christidis C, Mal F, Kazemi F, et al. Noninvasive assessment of liver fibrosis by measurement of stiffness in patients with chronic hepatitis C. *Hepatology* 2005;41:48-54.
10. Sporea I, Sirlin R, Deleanu A, Popescu A, Cornianu M. Liver stiffness

- measurement by transient elastography in clinical practice. *J Gastrointest Liver Dis* 2008;17:395-399.
11. Kim SU, Kim do Y, Park JY, Lee JH, Ahn SH, Kim JK, et al. How can we enhance the performance of liver stiffness measurement using FibroScan in diagnosing liver cirrhosis in patients with chronic hepatitis B? *J Clin Gastroenterol* 2010 ;44:66-71.
  12. Kim SU, Ahn SH, Park JY, Kang W, Kim do Y, Park YN, et al. Liver stiffness measurement in combination with noninvasive markers for the improved diagnosis of B-viral liver cirrhosis. *J Clin Gastroenterol* 2009;43:267-271.
  13. Mendoza J, Gómez-Domínguez E, Moreno-Otero R. Transient elastography (Fibroscan), a new non-invasive method to evaluate hepatic fibrosis. *Med Clin (Barc)* 2006;126:220-222.
  14. Baik SK, Kim JW, Kim HS, Kwon SO, Kim YJ, Park JW, et al. Recent variceal bleeding: Doppler US hepatic vein waveform in assessment of severity of portal hypertension and vasoactive drug response. *Radiology* 2006;240:574-580.
  15. Seitz JF, Boustière C, Maurin P, Aimino R, Durbec JP, Botta D, et al. Evaluation of ultrasonography in the diagnosis of cirrhosis. Retrospective studies of 100 consecutive tests. *Gastroenterol Clin Biol* 1983;7:734-739.
  16. Silva G, Fluxá F, Hojas R, Ruiz M, Iturriaga H. Portal venous flow (ultrasonography-Doppler) in patients with alcoholic liver cirrhosis. *Rev Med Chil* 1991;119:530-537.
  17. Gaiani S, Gramantieri L, Venturoli N, Piscaglia F, Siringo S, D'Errico A, et al. What is the criterion for differentiating chronic hepatitis from compensated cirrhosis? A prospective study comparing ultrasonography and percutaneous liver biopsy. *J Hepatol* 1997;27:979-985.
  18. Tüney D, Aribal ME, Ertem D, Kotiloğlu E, Pehlivanoglu E. Diagnosis of liver cirrhosis in children based on colour Doppler ultrasonography with histopathological correlation. *Pediatr Radiol* 1998;28:859-864.
  19. Colli A, Fraquelli M, Andreoletti M, Marino B, Zuccoli E, Conte D. Severe liver fibrosis or cirrhosis: accuracy of US for detection--analysis of 300 cases. *Radiology* 2003;227:89-94.
  20. Hung CH, Lu SN, Wang JH, Lee CM, Chen TM, Tung HD, et al. Correlation between ultrasonographic and pathologic diagnoses of hepatitis B and C virus-related cirrhosis. *J Gastroenterol* 2003;38:153-157.
  21. Macías Rodríguez MA, Rendón Unceta P, Navas Relinque C, Tejada Cabrera M, Infantes Hernández JM, Martín Herrera L. Ultrasonography in patients with chronic liver disease: its usefulness in the diagnosis of cirrhosis. *Rev Esp Enferm Dig* 2003;95:258-264.
  22. Zheng RQ, Wang QH, Lu MD, Xie SB, Ren J, Su ZZ, et al. Liver fibrosis in chronic viral hepatitis: an ultrasonographic study. *World J Gastroenterol* 2003;9:2484-2489.
  23. Nishiura T, Watanabe H, Ito M, Matsuoka Y, Yano K, Daikoku M, et al. Ultrasound evaluation of the fibrosis stage in chronic liver disease by the simultaneous use of low and high frequency probes. *Br J Radiol* 2005;78:189-197.
  24. Lu LG, Zeng MD, Wan MB, Li CZ, Mao YM, Li JQ, et al. Grading and staging of hepatic fibrosis, and its relationship with noninvasive diagnostic parameters. *World J Gastroenterol* 2003;9:2574-2578.
  25. Garcia-Tsao G, Friedman S, Iredale J, Pinzani M. Now there are many (stages) where before there was one: In search of a pathophysiological classification of cirrhosis. *Hepatology* 2010;51:1445-1449.
  26. Rosenberg WM, Voelker M, Thiel R, Becka M, Burt A, Schuppan D, et al. Serum markers detect the presence of liver fibrosis: a cohort study. *Gastroenterology* 2004;127:1704-1713.
  27. Berzigotti A, Abralde JG, Tandon P, Erice E, Gilibert R, García-Pagan JC, et al. Ultrasonographic evaluation of liver surface and transient elastography in clinically doubtful cirrhosis. *J Hepatol* 2010;52:846-853.
  28. Fung J, Lai CL, Seto WK, Yuen MF. The use of transient elastography in the management of chronic hepatitis B. *Hepatol Int* 2011;5:868-875.
  29. Foucher J, Chanteloup E, Vergniol J, Castéra L, Le Bail B, Adhoute X, et al. Diagnosis of cirrhosis by transient elastography (FibroScan): a prospective study. *Gut* 2006;55:403-408.
  30. Coco B, Oliveri F, Maina AM, Ciccorossi P, Sacco R, Colombatto P, et al. Transient elastography: a new surrogate marker of liver fibrosis influenced by major changes of transaminases. *J Viral Hepat* 2007;14:360-369.
  31. Sagir A, Erhardt A, Schmitt M, Häussinger D. Transient elastography is unreliable for detection of cirrhosis in patients with acute liver damage. *Hepatology* 2008;47:592-595.
  32. Arena U, Vizzutti F, Corti G, Ambu S, Stasi C, Bresci S, et al. Acute viral hepatitis increases liver stiffness values measured by transient elastography. *Hepatology* 2008;47:380-384.
  33. Mederacke I, Wursthorn K, Kirschner J, Rifai K, Manns MP, Wedemeyer H, et al. Food intake increases liver stiffness in patients with chronic or resolved hepatitis C virus infection. *Liver Int* 2009;29:1500-1506.
  34. Yun MH, Seo YS, Kang HS, Lee KG, Kim JH, An H, et al. The effect of the respiratory cycle on liver stiffness values as measured by transient elastography. *J Viral Hepat* 2011;18:631-636.
  35. Moore CL, Copel JA. Point-of-care ultrasonography. *N Engl J Med* 2011;364:749-757.
  36. Zwiebel WJ. Sonographic diagnosis of diffuse liver disease. *Semin Ultrasound CT MR* 1995;16:8-15.
  37. Kim MY, Baik SK, Park DH, Lim DW, Kim JW, Kim HS, et al. Damping index of Doppler hepatic vein waveform to assess the severity of portal hypertension and response to propranolol in liver cirrhosis: a prospective nonrandomized study. *Liver Int* 2007;27:1103-1110.